

RRST- Anatomy

Study of Basilar Artery Using Magnetic Resonance Imaging Angiography

M. Haripriya* and S. Melani Rajendran

Department of Anatomy, Sri Ramachandra Medical College & Research Institute, Sri Ramachandra University, Chennai

Article Info

Article History

Received : 27-06-2011
Revised : 25-07-2011
Accepted : 04-08-2011

*Corresponding Author

Tel : +91-9444057750

Email:
haripriya_67@yahoo.co.in

©ScholarJournals, SSR

Abstract

Basilar artery variations were studied in fifty patients using Three Dimensional Time of Flight Magnetic Resonance Imaging Angiography. Two basilar arteries showed variations and others found to be normal. In one case, the basilar artery showed stenosis and another case showed bulbosity. With the literature analysis, it was concluded that Magnetic Resonance Imaging Angiography is the best tool to show the anastomotic variations of the arteries of the brain and the most powerful non-invasive method for a reliable judgement for determining the degree of stenosis or any other pathology of vertebral-basilar system because it does not have the high morbidity associated with conventional intra-arterial angiography.

Key Words: Basilar artery, Stenosis, Bulbosity, Magnetic Resonance Imaging Angiography.

Introduction

Thrombosis of the basilar artery results in partial or complete obstruction of the basilar artery and has high morbidity and mortality. It can cause infarction and can be life threatening, as it leads to hypoxia and ischaemia of the brainstem. Basilar artery thrombosis is most often fatal with conservative therapy^{1,2,3}. It has been treated in recent years with intra-arterial thrombolytic agents in an attempt to improve survival⁴ and the survival is improved by basilar artery recanalisation. Poor prognoses are common and these can include paralysis of extremities, heavy disturbances in sensation, difficulty in swallowing and respiration. Basilar artery thrombosis is the most common cause of 'locked in syndrome' and cerebellar infarcts. Cerebellar infarcts can be classified as territorial and non territorial. Disarthria and ataxia are prominent in infarcts involving the area supplied by the superior cerebellar arteries.

Basilar artery is the most important artery in the posterior circulation of brain. It is formed by the union of two vertebral arteries (Fig.1) at the ponto-medullary junction and courses on the ventral aspect of the pons⁵. It terminates as the posterior cerebral arteries at the upper border of the pons which forms the posterior configuration of the circle of Willis. Anterior inferior cerebellar artery, labyrinthine artery, short pontine branches and superior cerebellar artery are its other branches. It supplies the lateral part of the tegmentum of the pons, middle cerebellar peduncle, flocculus and anterior and superior part of the cerebellum. Its terminal branch, the posterior cerebral artery supplies the thalamus, medial surface of the temporal and occipital lobes⁵.

A better understanding of the variations in the clinical picture is possible when looking at the arterial supply of the

cerebellum. This is mainly by three long circumferential arteries: the posterior inferior cerebellar arteries, branch of the vertebral artery, supplying the posterior inferior surface, the anterior inferior cerebellar arteries for the rostral surface and the superior cerebellar arteries to supply the tentorial surface which are the branches of the basilar artery.

The neurological deficit suffered as well as the ability of a patient to withstand occlusion of one or more of the major vessels of the brain depend on the presence of collateral circulation to the affected area. A detailed knowledge of the normal anatomy of the basilar artery and its anomalies and the clinical significance of its variations is valuable to the clinicians and neuroradiologists.

Therefore the present study was carried out to find out the variations of the basilar artery using Magnetic Resonance Imaging Angiography.

Materials and Methods

Fifty patients at random from the Out Patient Department of Radiology and Imaging Sciences, Sri Ramachandra Medical College and Research Institute, Sri Ramachandra University for undergoing MRI were chosen for the study. The technique used was Three Dimensional Time of Flight Magnetic Resonance Angiography (3D-TOF-MRA). Only the basilar artery and the arteries forming the circle of Willis were studied. For the purpose of identification, the circle of Willis is divided into anterior and posterior configurations. The anterior configuration consisting of the anterior cerebral artery, anterior communicating artery and internal carotid artery. The posterior configuration consisting of posterior cerebral artery, posterior communicating artery and basilar artery.

Observations

Out of the fifty cases, only two cases showed variations of the basilar artery whereas others were found to be normal (Fig.1).

The findings were:

1. Stenosis of basilar artery in one case (Fig. 2).
2. Bulbosity of basilar artery (Fig. 3).

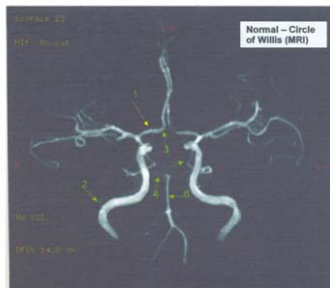


Fig.1 showing normal circle of Willis. 1. Anterior cerebral artery 2. Internal carotid artery 3. Anterior communicating artery 4. Posterior cerebral artery 5. Posterior communicating artery 6. basilar artery

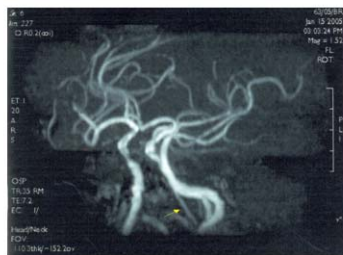


Fig.2 showing stenosis of the basilar artery. Arrow indicates stenosis

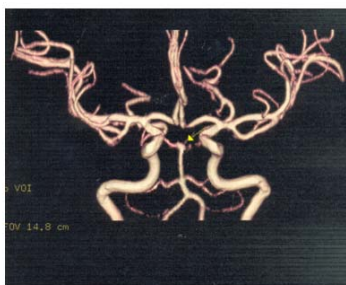

Fig.3 showing bulbosity of the basilar artery. Arrow indicates bulbosity

Discussion

Although various studies had been carried out to investigate the variations of the circle of Willis by many investigators 6, 7, 8, 9, 10, less investigations had been made on the variations of the basilar artery to clarify the clinical importance. In the present study in one case, the basilar artery showed ectatic change at its bifurcation which may be due to aneurysm. The basilar artery aneurysm can cause stroke which may be due to thrombosis of the perforating arteries, arterio-arterial emboli or a compressive mechanism. Since sub arachnoid haemorrhage secondary to rupture of a dolichoectasia is exceptional, some authors support the use of permanent anticoagulation rather than platelet antiaggregation in patients with ischaemia, where dilatations are limited to the basilar artery 11. In one case basilar artery showed stenosis. It is

an important step in the diagnosis and must assess the degree of stenosis, the smoothness of the plaque and the collateral vessels (Rolland *et al.*, 1996). In the observations of Szabok *et al.* (2001), statistical analysis showed a significant relationship between the degree of stenosis and observed stroke pattern. Although in the individual patient, any of the infarct patterns may occur, in statistical terms the incidence of a particular stroke pattern is clearly dependent on the degree of stenosis. Therefore territorial stroke can occur in basilar artery stenosis.

Symptomatic patients with acute proximal artery thrombosis had little chance of survival after thrombolysis, independent of the degree of collateral filling of the basilar artery. Taking together with prior reports, it appears that the favourable prognostic factors for patients with symptomatic basilar artery thrombosis undergoing intra-arterial thrombolysis include distal clot location, complete basilar artery recanalization and collateral filling of the basilar artery 4.

Even in normal individuals, the accurate identification of the intracranial segments of the vertebral arteries and basilar artery and their discrimination from cerebellar arteries can be difficult 12,13. The signal intensity of blood flow within a vessel is dependent on the replenishment of fully magnetized spins at the entry of the imaging section. Accordingly, non-visualization of a vessel may be either due to the absence of the vessel or to a very slow or turbulent flow within the vessel itself. Both atherosclerotic and non-atherosclerotic basilar artery disease can be comprehensively assessed with contrast enhanced Magnetic Resonance Angiography. Contemporary understanding of the collateral circulation may be greatly enhanced through further refinement of neuro imaging modalities that correlate angiographic findings with perfusion status, providing the basics for future therapeutic and prognostic applications.

Therefore it can be concluded that MRI is the most powerful non-invasive method for a reliable judgement for determining the degree of stenosis or any other pathology of vertebral-basilar system because it does not have the high morbidity associated with conventional intra-arterial angiography.

References

- [1] Kubik, C.S. and Adams.1946. Occlusion of the basilar artery: a clinical and pathological study. *Brain*.59:73-121.
- [2] Biemond. A.1951. Thrombosis of the basilar artery and the vascularization of the brainstem. *Brain*.74:300-317.
- [3] iekert, R.G. and C.H. Millikan. 1995. Studies in cerebrovascular disease, II: Some clinical aspects of the thrombosis of the basilar artery. *Proc Mayo Clin*. 30:93 - 100.
- [4] De Witte. T. Cross, III, Chrostopher J. Moral, Paul T. Akins, Edward E. Angtuaco, Colin P. Derdeyn, and Michael N. Diringner.1998. Collateral Circulation and Outcome after Basilar Artery Thrombolysis. *JNR Am J Neuroradiol* 19:1557-1563.
- [5] Williams PL, Bannister LH, Berry MM. 1995. Haemolymphoid System In: *Gray's Anatomy*, 38th Edition, Edinburgh and London: ELBS with Churchill Livingstone. pp. 571-574.
- [6] Al Hussein SM, Shoter AM and Bataina ZM . 2001. Circle of Willis. *Saudi Med J*, 22: 895 – 898.

- [7] HariPriya, M and Melani Rajendran. 2010. Variations of circle of Willis. *International Journal of Anatomical Sciences*. 1: 26-30.
- [8] Macchi C, Lova RM, Miniati B, Gulisano M, Pratesi C, Conti AA and Gensini GF.2002.The Circle of Willis in healthy older persons. *J Cardiovasc Surg (Torino)*, 43: 887 – 890.
- [9] Voljevica A, Kulenovic A, Kapur E, Talovic E, Vuckovic I, Luinovic .2004.Presentations of variations in the anterior part of the Circle of Willis as a result of MRI- angiography method. *Med Arh*, 58: 327 – 330.
- [10] Brunereau L, Levy C, Bousson V, Marsot – Dupuch K, Bousser MG and Tubiana JM.1995. Anatomy of the Circle of Willis with 3D time of flight magnetic resonance angiography and analysis of partitions. *J Radio*, 76: 573 – 577.
- [11] Arenas-Cabera C, Martinez-Fernandez E, Gil-peralta A, Sanchez-Huelva A, Cabrera-Perez R and Chinchon-Lara T. 2001.Repeated strokes in a patient with a basilar artery aneurysm. *Rev Neuro*, 32: 335-338.
- [12] von Budinggen HJ ,and Staudacher, T.1992.Evaluation of vertebrobasilar disease. In: Newell D W, Aaslid Redas. 1992.Transcranial Doppler.New york, NY: Raven Press publishers: 167-195.
- [13] Ringelstein EB, Kahlscheuer B, Niggemeyer E, Otis SM.1990.Transcranial Doppler sonography:anatomical landmarks and normal velocity values. *Ultrasound Med Biol*. 16:745-761.