

Study of *Eimeria necatrix* in broiler chicken from Aurangabad District of Maharashtra state India

B.N.Jadhav¹, S.V.Nikam², S.N.Bhamre³ and E. L. Jaid⁴

¹Shri Muktanand College Gangapur Tq Gangapur Dist.Aurangabad (M.S.), India

²Department of Zoology, Dr.Babasaheb Ambedkar Marathwada University Aurangabad, (M.S.), India

³K.R.A. college, Deola Dist.Nashik.(M.S.),India

⁴Parth Sainiki Science College, Jalna (M.S.), India

Abstract

The objective of this study was first to investigate the prevalence of poultry coccidiosis and to identify the coccidial species occurring in the study area on local strain. The study involved survey, fecal examination, and identification of coccidial species based on their morphology, predilection site in the intestine and sporulation time. During the present study ten species of *Eimeria* are found in Broiler chicken. Seven species are redescribed and three are new species.

Keywords: Coccidiosis, broiler chicken, *Eimeria Sp.*

INTRODUCTION

Coccidiosis is the major problem in poultry worldwide. In our country, it causes serious problem and causing huge economic loss to poultry industry, especially in the production of Broiler chicken. Study of species composition in protozoa is addition to science.

Avian coccidiosis, an intestinal disease caused by protozoan parasites of the genus *Eimeria*, occurs worldwide. It is considered to be one of the most economically important diseases of domestic poultry. For many years, prophylactic use of anticoccidial feed additives has been the primary means of controlling coccidiosis in the broiler industry and has played a major role in the growth of this industry, which now can produce about 7.6 billion chickens annually. However, development of anticoccidial resistance has threatened the economic stability of the broiler industry. Coccidiosis is believed to be a commonest depreciator or even a potential killer of our poultry. So medical point of view their study is very important. My study covers survey and species composition of coccidia i.e. various species of genus *Eimeria* from chicken.

MATERIALS AND METHODS

The material for the study of coccidia of Broiler chicken was obtained from various slaughter houses as well as from different fields in Aurangabad district (M.S.). The different parts of the intestine of slaughtered chicken were examined and processed within 4-5 hours after collection. The samples were examined for the presence of oocysts. Oocysts are separated from fecal material by sieving and centrifugation at 3000 rpm for 10 min. The oocysts collected were spread out in shallow Petri dish in 2.5% potassium

dichromate solution for sporulation.

RESULTS AND DISCUSSION

During the present study ten species of *Eimeria* are identified in Broiler chicken. Seven species are redescribed and three are new species. *Eimeria necatrix* was the second common species found in 143 out of 734 positive samples representing 19.48% of the positive samples and 5.66% of the total samples examined. The pure infections were found in 338 out of the 734 positive samples and 2524 of the total samples in Broiler chicken representing 46.04% of the positive samples or 13.39% of the total samples. All the ten species have been recorded in pure infections though in varying frequencies. The *Eimeria necatrix* being found in 37 out of 338 pure samples, representing 10.94% in the pure samples and 5.04% in total positive samples.

Description of the oocyst: *Eimeria necatrix*

The oocysts are oblong ovoid in shape and covered by double layered wall. The outer wall is thick and pale yellow in colour while inner is thin and brownish. Wall thickness is about 1.2um thick. Micropyle and micropylar cap is absent. The unsporulated oocyst shows a small and spherical sporoblast filling central portion of the oocyst. The sporulated oocyst shows the presence of prominent polar granule at the anterior end just behind the oocyst wall. No oocystic residuum is seen. The sporocysts are typically pyriform in shape, measure about 8.16-13.26 um in length and 5.12-6.12 um in width. Posterior end of the sporocyst is rounded; broad, anterior end is narrow, tapering with large stieda body. Sporocystic residuum is absent. The sporozoites are bean shaped and carry a large prominent retractile body.

The dimensions of the sporulated oocysts are as follows:-
(All measurements are in microns.)

Received: Oct 14, 2011; Revised: Nov 24, 2011; Accepted: Dec 16, 2011.

*Corresponding Author

B.N.Jadhav
Shri Muktanand College Gangapur Tq Gangapur Dist.Aurangabad (M.S.),
India

Email:

Particulars	Cyst from broiler chicken
Length of the oocyst	13.2 - 22.5 (16.2)
Width of the oocyst	11.0 - 18.7 (15.7)
Length width ratio	1.2 - 1.4 (1.3)
Length of the sporocyst	8.1 - 13.2 (10.7)
Width of the sporocyst	5.1 - 6.1 (5.7)
Length width ratio of the sporocyst	1.5 - 2.1 (1.8)

Sporulation time

The sporulation time of the oocysts was 18-24 hours.

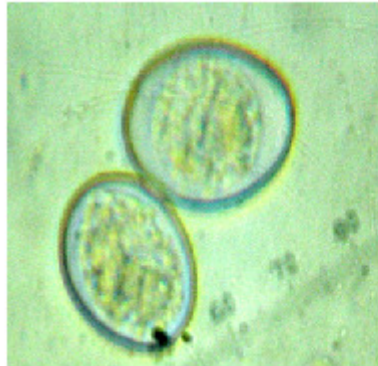

Fig 1. Unsporulated oocyst of *Eimeria necatrix*

Prevalence

The species was found in 5.66% of the 2524 broiler chicken examined from Aurangabad region (M.S.).

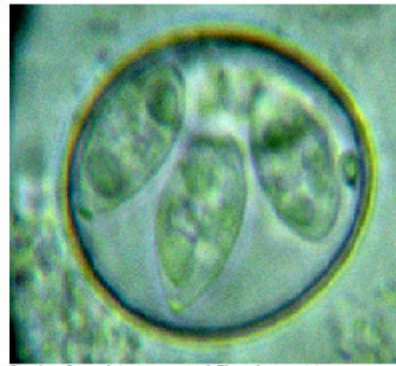


Fig 2. Sporulated oocyst of *Eimeria necatrix*

COMMENTS

This species was first described from chicken by Johnson in 1930 at Western Washington of U.S. and later on by various workers in the different parts of the world like Tyzzer (1932) [1] at Harvard university. In India various workers work on coccidia of birds [2] work on domestic fowl.

The description of the sporulated oocyst given here agrees in general with those of earlier workers. There is however minor variations in the morphometrics.

ACKNOWLEDGEMENT

The authors are grateful to the Head, Deptt. of Zoology Dr.B.A.M. University, Aurangabad (M.S.) for his kind cooperation encouragement and facilities extended.

REFERENCES

- [1] Tyzzer, E.E. (1932). Criteria and methods in the investigation of avian coccidiosis. *Science*.75 (1943): 324-328.
- [2] Ray, D.K, Shivmani, G.A.Oomen, and Bhaskaran, R. (1952). *A study on the coccidia of some Himalayan birds.*